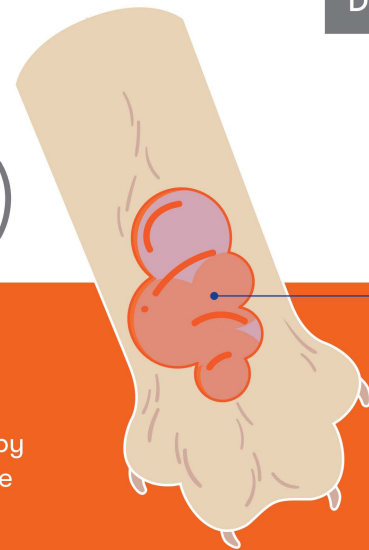


Lick granuloma (acral lick dermatitis)

A lick granuloma is a patch of hairless, thickened, and irritated skin caused by repeated licking or chewing.

Lick granulomas may be caused by behavior factors like boredom or stress, or by skin conditions like allergies, infection, irritation, or fleas; or by undiagnosed pain from joints or soft tissues. They are often seen on active or easily bored dogs that are left at home, or in a crate, for many hours.



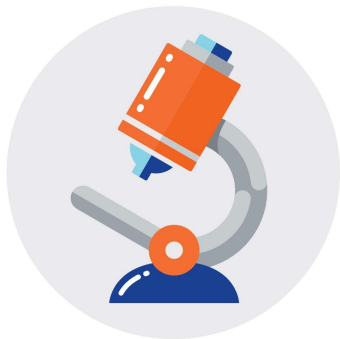Thickened,
hairless,
inflamed skin

- ▶ Once a granuloma is formed, it may create a cycle of irritation and licking.

What does it look like?

Common signs:

- Frequent licking or chewing at the skin
- A thickened, hairless area (typically on the lower leg)
- A tumor-like growth



How is it diagnosed?

- Your pet's history
- Clinical signs, like hairless areas
- Laboratory skin or blood tests
- Physical exam results
- Response to treatment
- X-rays

- ▶ Your pet may need further testing to find any underlying causes of their lick granuloma.

How is it treated?

Treatment depends on the severity and duration of the problem.

- Prevent licking by wrapping the area, applying topical medications, and using an anti-lick substance or e-collar
 - Some pets may need antibiotics and behavior-modifying medications
 - Environmental enrichment can help to prevent boredom that may lead to licking
- ▶ Pets with chronic lick granulomas need careful monitoring to catch new areas early.



How to help your pet

- Administer all medications as directed
- Follow all wound care and bandage instructions, and make sure your pet wears their e-collar at all times
- Monitor your pet's progress and schedule checkups as directed
- Contact your veterinary team with any questions
- Need immediate advice? Ping Vet Chat™—included in all pet Optimum Wellness Plans®!

